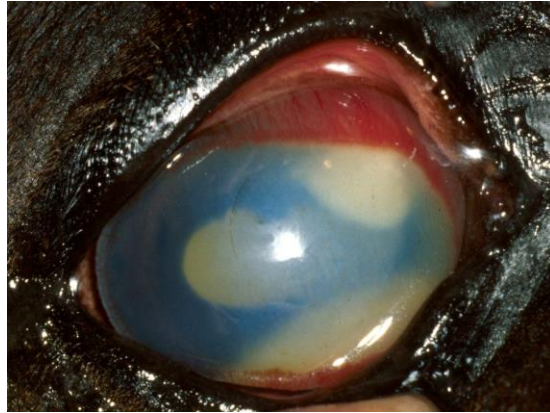

## Equine Nonulcerative Keratopathies



Dennis E. Brooks, DVM, PhD  
Diplomate, American College of Veterinary Ophthalmologists  
Professor of Ophthalmology  
[brooksd@ufl.edu](mailto:brooksd@ufl.edu)

### **CORNEAL STROMAL ABSCESSSES**

Focal trauma to the cornea can inject microbes and debris into the corneal stroma through small epithelial ulcerative micropunctures. Some stromal abscesses may be secondary to systemic disease. A corneal abscess may develop after epithelial cells adjacent to the epithelial micropuncture divide and migrate over the small traumatic ulcer to encapsulate infectious agents or foreign bodies in the stroma. Epithelial cells are more likely to cover a fungal than a bacterial infection. Reepithelialization forms a barrier that protects the bacteria or fungi from topically administered antimicrobial medications. Reepithelialization of stromal abscesses interferes with both routine diagnostics and treatment.

Corneal stromal abscesses can be a vision threatening sequelae to apparently minor corneal ulceration in the horse. A painful, blinding chronic iridocyclitis may result. Most stromal abscesses involving Descemet's membrane are fungal infections. The fungi seem "attracted" to the type IV collagen of Descemet's membrane.

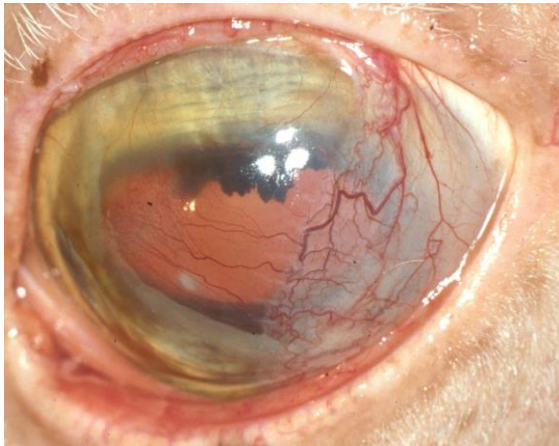
Both superficial and deep stromal abscesses do not heal until they become vascularized. The patterns of corneal vascularization are often unique suggesting that vasoactive factors are being released from the abscess that influences the vascular response.

Medical therapy consists of aggressive use of topical and systemic antibiotics, topical atropine, and topical and systemic NSAIDs. Superficial stromal abscesses may initially respond positively to medical therapy. If reduced inflammation of the cornea and uvea are not found after two to three days of medical treatment, surgical removal of the abscess should be considered.

Deep lamellar and penetrating keratoplasties (PK) are utilized in abscesses near Descemet's membrane, and eyes with rupture of the abscess into the anterior chamber. PK eliminates sequestered microbial antigens, and removes necrotic debris, cytokines and toxins from degenerating leukocytes in the abscess.

### **Penetrating Keratoplasty (PK) for Deep Corneal Stromal Abscesses**

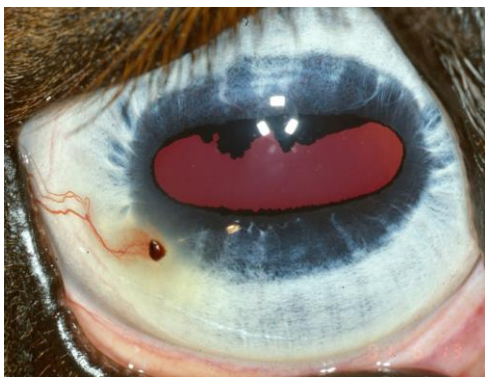Corneal transplantation is performed to restore vision, to control medically refractory corneal disease, and to re-establish the structural integrity of the eye. Penetrating keratoplasty is considered high-risk for rejection in infected, vascularized corneal tissue. Nearly all PKs in horses are in high-risk corneas. Fresh corneal grafts are preferred in horse PK, but frozen tissue can be utilized. Vascularization of the grafts, indicating rejection, begins at 5-10 days postoperatively. Few equine PK grafts remain clear following their vascularization. They form a therapeutic and tectonic function.



**Squamous cell carcinoma and other corneal**

### **tumors**

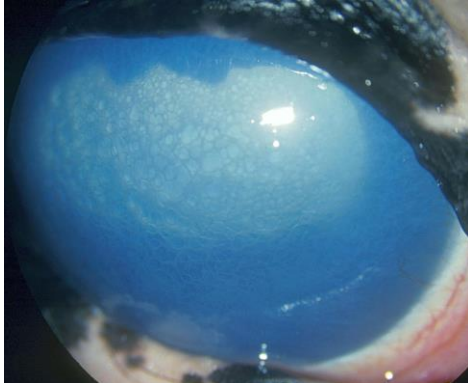
Preneoplastic epithelia dysplasia, intraepithelial carcinoma in situ, and the invasive squamous cell carcinoma (SCC) are common to the limbus and cornea of horses. Epithelial dysplasia can be treated with topical 5-fluorouracil. Keratectomy and adjunctive therapies are needed for carcinoma in situ and SCC. Rapidly progressive and invasive SCC may necessitate enucleation. Limbal melanomas and hemangiosarcomas have also been reported.



**Corneal foreign bodies**

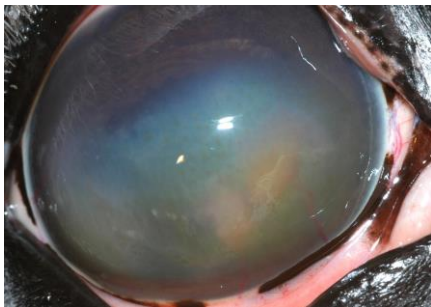
Penetrating and perforating corneal foreign bodies cause varying degrees of keratitis

and uveitis and are common in horses. Superficial foreign bodies can be removed under topical anesthesia and the subsequent ulcer treated medically. Deep corneal and penetrating foreign bodies may cause severe uveitis/endophthalmitis and require more aggressive care.



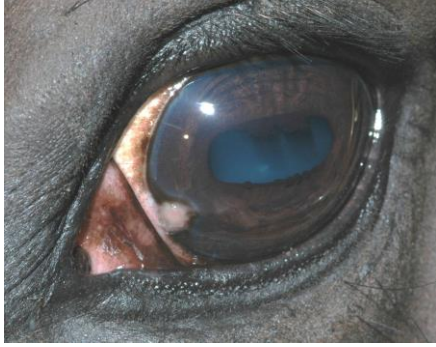#### **Endothelial detachment following blunt trauma**

Profound and persistent corneal edema may be present following blunt trauma to the globe of the horse. Detachment of the endothelium is a proposed mechanism of this syndrome. The prognosis for a return to normal is poor. Hypertonic solutions (5% sodium chloride) may be beneficial in the early stages. Thermatokeratoplasty may be necessary to reduce the edema in severe cases. Endothelial cell reattachment and cellular hypertrophy can occur to resolve the condition in some horses.



#### **Immune Mediated Keratitis**

Several forms of IMMK are found in the USA and Europe. Epithelial, stromal and endothelial types are noted. Some are associated with a “history of ocular trauma”. The etiology is presumed to be altered corneal immune privilege from abnormal exposure or expression of corneal antigens inducing autoimmune dysregulation. Nonulcerative superficial and nonulcerative recurrent forms of stromal keratitis are two types of IMMK are noted in warmbloods. Stromal pigmentation may occur in some eyes. An endotheliitis with slight corneal edema is another form of IMMK. These eyes may partially respond to topically administered corticosteroids, NSAIDs, tacrolimus or cyclosporine A, and may require parenteral antibiotics, corticosteroids, or NSAIDs.



### **Eosinophilic keratoconjunctivitis**

Eosinophilic keratoconjunctivitis has an unknown etiology, but may be an immune-mediated disease. All ages and breeds of horses can be affected with many cases reported in the spring. Clinical signs include corneal granulation tissue, blepharospasm, chemosis, conjunctival hyperemia, mucoid discharge, and corneal ulcers covered by raised, white, necrotic plaques. Eosinophilic keratoconjunctivitis resembles a corneal tumor in appearance.

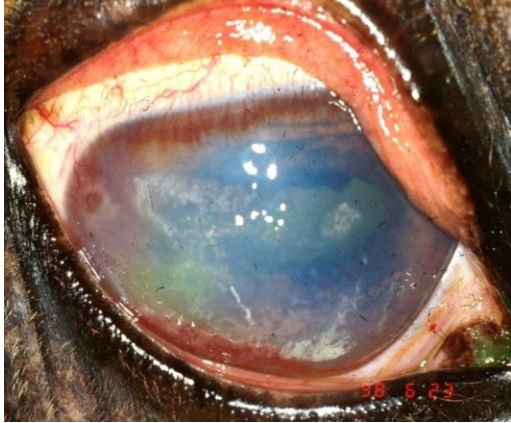
KCS may develop in affected horses due to lacrimal gland inflammation. The lacrimal gland should be palpated to detect swelling. Corneal cytology typically contains numerous eosinophils and a few mast cells to rule out similar appearing infectious and neoplastic causes.

Superficial lamellar keratectomy to remove plaques speeds corneal healing. Topical corticosteroids (1% prednisolone acetate or 0.1% dexamethasone) 4 to 6 times a day in early stages (in spite of corneal ulcerations), antibiotics (e.g., bacitracin-neomycin-polymyxin or chloramphenicol), 1% atropine, and 0.03% phospholine iodide (BID) in combination with systemic nonsteroidal antiinflammatory drugs are indicated. Topical cromolyn sodium (4.0% TID) or lodoxamide (0.1% TID), mast cell stabilizers, can also aid healing. Systemic corticosteroids may be necessary. Horses with EK should be dewormed twice with ivermectin 10 days apart. Alternative dewormers should also be considered. These lesions are typically slow to heal. Scarring of the cornea occurs frequently.

### **Herpes keratitis**

Multiple, superficial, white, punctate or linear opacities of the cornea, with or without fluorescein dye retention, are found associated with equine herpes virus 2. The focal punctate corneal opacities may be found at the end of superficial corneal vessels, and may retain rose bengal stain. Varying amounts of ocular pain, conjunctivitis, and iridocyclitis are present. Multiple foals in a herd may be affected.

Topically administered idoxuridine and trifluorothymidine (TID) have been used with topical NSAIDs for treatment of equine herpes ulcers, but recurrence is common.



### **Calcific band keratopathy**

Calcific band keratopathy (CBK) is a complication of chronic uveitis and consists of deposition of dystrophic calcium in the superficial corneal epithelium and stroma. Dense, white bands of calcium are noted in the interpupillary region of the central cornea. Scattered areas of fluorescein retention are present as the calcium disrupts the epithelium to result in painful superficial ulcers. Deep ulcers can develop. A gritty sensation is found during scraping for corneal cytology. It appears to develop in the eyes of horses most aggressively treated with topical corticosteroids for ERU. CBK is rare in ERU horses that have not been treated medically!

Treatment is topically administered calcium chelators (dipotassium ethylene diamine tetraacetate 13.8%, Sequester-Sol(r)) to decrease tear calcium levels and aid healing. Topical antibiotics, atropine, and systemic non-steroidal anti-inflammatory drugs are also beneficial for the ulcers. Superficial keratectomy may be necessary to remove the painful calcium deposits. Healing of keratectomy sites can occur with severe scarring. Recurrence of calcium band keratopathy is possible with continued episodes of uveitis. The prognosis for vision is guarded because of subsequent corneal scarring and further uveitis episodes.

### **Reference**

Gelatt KN: Veterinary Ophthalmology 5<sup>th</sup> Ed, Lippincott, Williams and Wilkins, Philadelphia, 2013.

Brooks DE: Ophthalmology for the Equine Practitioner. Teton NewMedia, Jackson, WY, 2008.

Gilger BC (ed): Equine Ophthalmology, Ed 2. Elsevier, Maryland Heights, MO, 2010.

Clinical Techniques in Equine Practice: Equine Ophthalmology, 4(1); 2005.