

## **THERAPY OF DEEP AND MELTING ULCERS IN THE HORSE**

Dennis E. Brooks, DVM, PhD

Diplomate, American College of Veterinary Ophthalmologists

Professor of Ophthalmology

University of Florida

[brooksd@ufl.edu](mailto:brooksd@ufl.edu)

Corneal ulcers in horses should be aggressively treated no matter how small or superficial they may be. Corneal infection and iridocyclitis are always major concerns for even the slightest corneal ulcerations. Iridocyclitis or uveitis is present in all types of corneal ulcers and must be treated in order to preserve vision. Globe rupture, phthisis bulbi, and blindness are possible sequelae to corneal ulceration in horses.

### *Corneal Healing in the Horse*

Healing of large diameter, superficial, noninfected corneal ulcers is generally rapid and linear for 5-7 days, and then slows. The epithelial basement membrane is not completely formed six weeks following corneal injury in the horse, in spite of the epithelium completely covering the ulcer site. Slow healing of ulcers is related to increased tear proteinase activity. Healing time of a 7-mm diameter, midstromal depth, noninfected corneal trephine wound was nearly 12 days in horses (0.6 mm/day). Neutrophils move into the horse cornea at 8 mm/day!!! Blood vessels move at 1 mm/day.

### *The Equine Corneal Microenvironment*

The environment of the horse is such that the conjunctiva and cornea are constantly exposed to bacteria and fungi. Infection should be considered likely in every corneal ulcer in the horse. Fungal involvement should be suspected if there is a history of corneal injury with vegetative material, or if a corneal ulcer has received prolonged antibiotic and/or corticosteroid therapy with slight or no improvement. Tear film neutrophils and some bacteria and fungi are associated with highly destructive proteinase and collagenase enzymes that can result in rapid corneal stromal thinning, descemetocele formation, and perforation. Excessive proteinase activity is termed "melting", and results in a liquefied, grayish-gelatinous appearance to the stroma near the margin of the ulcer.

Total corneal ulceration ultimately requires the degradation of collagen that forms the framework of the corneal stroma. Horse corneas demonstrate a pronounced fibrovascular healing response. The unique corneal healing properties of the horse in regards to excessive corneal vascularization and fibrosis appear to be strongly species specific.

Ulcers, uveitis, blepharitis, conjunctivitis, glaucoma, and dacryocystitis must be considered in the differential for the horse with a painful eye. Corneal edema may surround the ulcer or involve the entire cornea. Signs of anterior uveitis are found with every corneal ulcer in the horse, and include miosis, fibrin, hyphema or hypopyon. Persistent superficial ulcers may become indolent due to hyaline membrane formation on the ulcer bed.

Fluorescein dye retention is diagnostic of a full thickness epithelial defect or corneal ulcer. Faint fluorescein retention may indicate a microerosion or partial epithelial cell layer defect due to infiltration of fluorescein dye between inflamed epithelial cell junctions. All corneal injuries

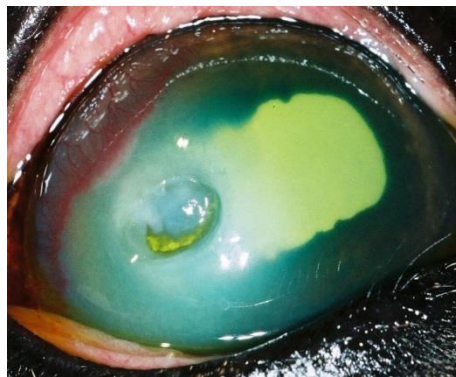
should be fluorescein stained to detect corneal ulcers. Rose bengal retention indicates a defect in the mucin layer of the tear film. RB can be obtained at [www.akorn.com](http://www.akorn.com)

Horses with painful eyes need to have their corneas stained with both fluorescein dye and rose bengal dye as fungal ulcers in the earliest stage will be negative to the fluorescein but positive for the rose bengal. Fungi may induce changes in the tear film mucin layer prior to attachment to the cornea. Early fungal lesions that retain rose bengal are multifocal in appearance and may be mistaken for viral keratitis.

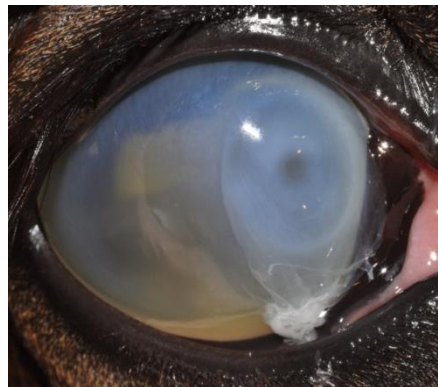Microbiologic culture and sensitivity for bacteria and fungi are recommended for horses with rapidly progressive, and deep corneal ulcers. Corneal cultures should be obtained first and then followed by corneal scrapings for cytology. Mixed bacterial and fungal infections can be present.

Vigorous corneal scraping at the edge and base of a corneal ulcer is used to detect bacteria and fungal hyphae. Samples can be obtained with the handle end of a sterile scalpel blade and topical anesthesia. Superficial scraping with a cotton swab cannot be expected to yield organisms in a high percentage of cases.

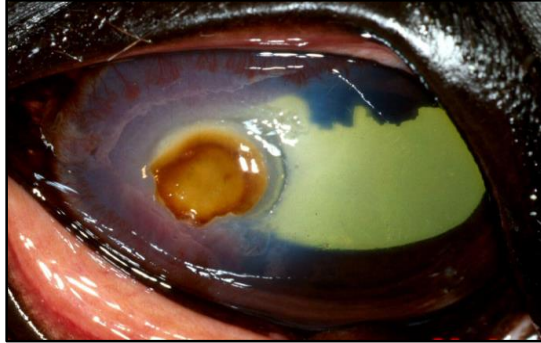Deep penetration of the stroma to Descemet's membrane with perforation of the cornea is a possible sequelae to all corneal ulcers in horses.



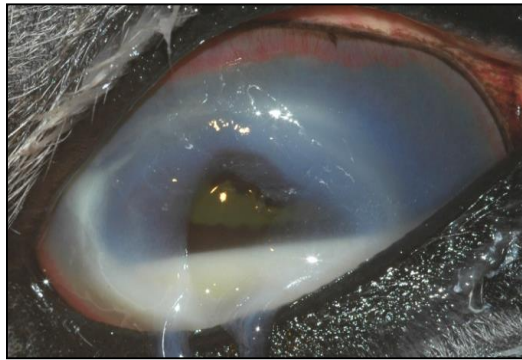
Melting Deep Ulcer



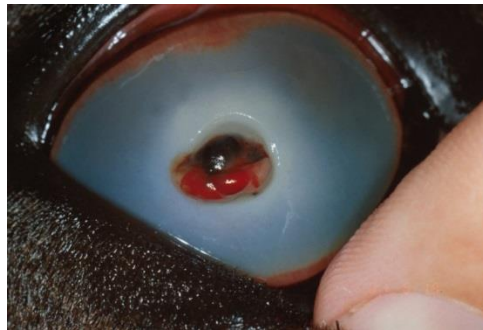**Deep melting ulcers associated with keratomycosis**



**Plaques associated with keratomycosis**



**Descemetocoeles associated with keratomycosis**



**Iris prolapse associated with keratomycosis**

*Medical therapy: infection, hyperproteinase activity, uveitis*

Once a corneal ulcer is diagnosed, medical therapy almost always comprises the initial major thrust in ulcer control, albeit tempered by judicious use of adjunctive surgical procedures.

### *Antibiotics*

Bacterial and fungal growth must be halted and the microbes rendered non-viable. Broad-spectrum topical antibiotics are usually administered with culture and sensitivity tests aiding selection. Topical antibiotic solutions interfere with corneal epithelial healing less than ointments. Gentamicin should be used in ulcers with evidence of stromal melting only.

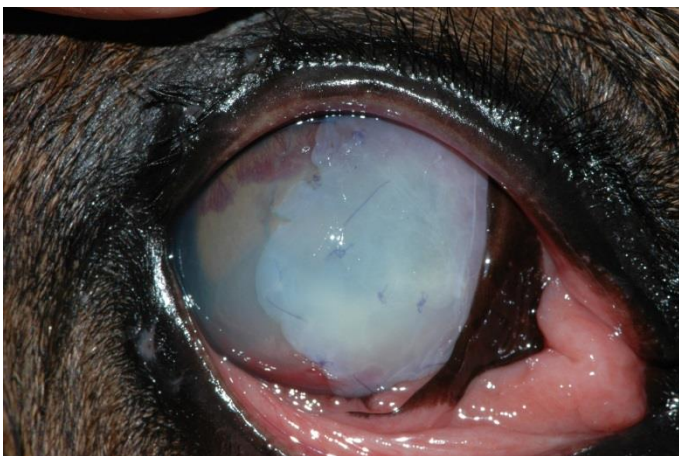
Topically applied antibiotics, such as chloramphenicol, bacitracin-neomycin-polymyxin B, gentamicin, ciprofloxacin, or tobramycin ophthalmic solutions may be utilized to treat bacterial ulcers. Frequency of medication varies from q2h to q8h. Cefazolin (55mg/ml), chloramphenicol, bacitracin, and carbenicillin are effective against beta hemolytic *Streptococcus*. Ciloxan (ciprofloxacin), amikacin (10 mg/ml), and polymyxin B (0.25% IV solution) may be used topically for gentamicin resistant *Pseudomonas*.

The fungi are overall more susceptible to antifungal drugs in this order: natamycin = miconazole > itraconazole > ketoconazole > fluconazole. Natamycin, miconazole, itraconazole/DMSO, fluconazole, amphotericin B, betadine solution, chlorhexidine gluconate, posaconazole, voriconazole, and silver sulfadiazine can be utilized topically. The antifungals can be given q2h to q8h.

### *Collagenolysis prevention*

Severe corneal inflammation secondary to bacterial (especially, *Pseudomonas* and beta hemolytic *Streptococcus*) or, much less commonly, fungal infection may result in sudden, rapid corneal liquefaction and perforation. Activation and/or production of proteolytic enzymes by corneal epithelial cells, leucocytes and microbial organisms are responsible for stromal collagenolysis or “melting”.

Serum is biologically nontoxic and contains an alpha-2 macroglobulin with antiprotease activity. Autogenous serum administered topically can reduce tear film and corneal protease activity in corneal ulcers in horses. The serum can be administered topically as often as possible, and should be replaced by new serum every 8 days. Five to 10 per cent acetylcysteine, and/or 0.05% sodium EDTA can be instilled hourly, in addition to the other indicated drugs, for antimelting effect until stromal liquefaction ceases.



Amnion placed over melting cornea

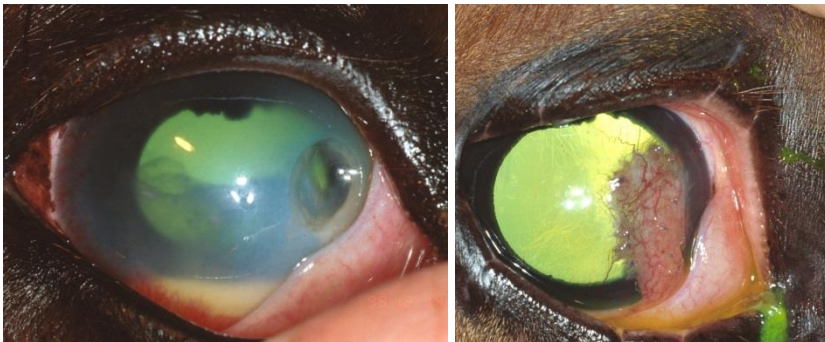### *Treat Uveitis*

Atropine may be utilized topically q4h to q6h with the frequency of administration reduced as soon as the pupil dilates. Systemically administered NSAIDs such as phenylbutazone (1 gm BID PO) or flunixin meglumine (1 mg/kg BID, IV, IM or PO) can be used orally or parenterally, and are effective in reducing uveal exudation and relieving ocular discomfort from the anterior uveitis in horses with ulcers. Topical nonsteroidal antiinflammatory drugs (NSAIDs) such as flurbiprofen and diclofenamic acid (BID to TID) can also reduce the degree of uveitis.

### *Surgical Therapy*

#### *Conjunctival Flaps*

Conjunctival grafts or flaps are used frequently in equine ophthalmology for the clinical management of deep, melting, and large corneal ulcers, descemetocelles, and for perforated corneal ulcers with and without iris prolapse. To augment lost corneal thickness and strength, deep corneal ulcers threatening perforation may require conjunctival flap placement. Conjunctival flaps are associated with some scarring of the ulcer site. Coverage with a 360°, hood, island, pedicle, or bridge flap should be maintained for 4 to 12 weeks. Reoccurrence of the inflammation may occur following flap removal. A conjunctival pedicle flap is made by incising conjunctiva (excluding Tenon's capsule) 1-2 mm posterior to and parallel to the limbus with Steven's tenotomy scissors. The flap is undermined posteriorly toward the fornix as needed. A perpendicular incision is made at the distal end of the flap, and an incision parallel to the first incision and limbus is made several millimeters posterior to the first incision. The flap is rotated over the defect and sutured in place with absorbable 5-0 to 7-0 suture.

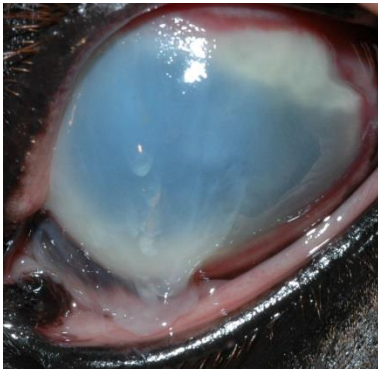


Pedicle Flap

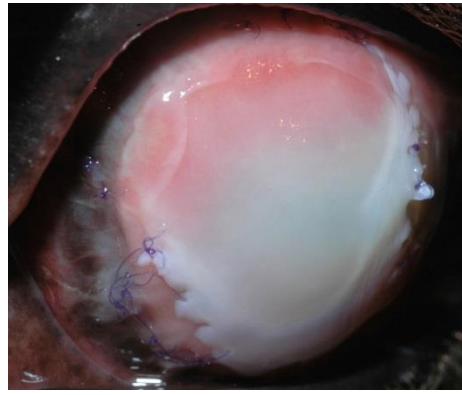
#### *Amniotic Membrane Flaps*

Amniotic membrane transplantation may provide decreased fibrosis, reduced vascularization of corneal ulcers, and faster reepithelialization in horses with superficial and/or deep corneal ulcers. They may be used alone or with conjunctival flaps.

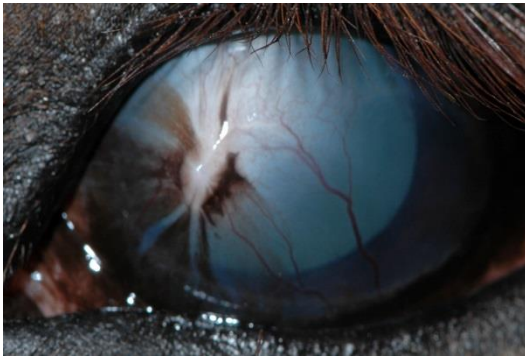




Cornea



Amnion placed over melting



Healed with amnion.

### *Third-Eyelid (TE) Flaps*

Nictitating membrane flaps are used for superficial corneal diseases including corneal erosions, neuroparalytic and neurotropic keratitis, temporary exposure keratitis, superficial corneal ulcers, superficial stromal abscesses, and to reinforce a bulbar conjunctival graft. Formation of a third-eyelid flap with attachment to the upper eyelid is performed by placing 2-4 horizontal mattress sutures. Initially pass the cutting needle through the upper eyelid through the fornix at the desired location. Direct the needle (3-0 suture) through the anterior face of the TE approximately 3 mm from the leading edge, and then again in the skin through the fornix adjacent to the first bite. These sutures should not be full-thickness in the TE. One to three additional sutures are placed and then tied.

### *Enucleation*

Panophthalmitis following perforation of an infected corneal stromal ulcer has a poor prognosis. Phthisis bulbi is likely to result after a chronically painful course. Affected horses can be febrile and manifest signs of septicemia. To spare the unfortunate animal this discomfort, enucleation is the humane alternative. Histopathologic examination of the globe is recommended.

### *Inappropriate therapy and ulcers*

Topical corticosteroids may encourage growth of bacterial and fungal opportunists by interfering with non-specific inflammatory reactions and cellular immunity. Corticosteroid therapy by all routes is contraindicated in the management of corneal infections. Even topical corticosteroid instillation, to reduce the size of a corneal scar, may be disastrous if organisms remain indolent in the corneal stroma.

### **References/Suggested Reading**

Brooks DE: Equine Ophthalmology. Ed 2. Teton NewMedia, Jackson, WY, 2008.

Gilger BC (ed): Equine Ophthalmology ed 2, WB Saunders, Philadelphia, 2011.

Brooks DE, Matthews AG: Equine Ophthalmology, In Gelatt KN (ed), Veterinary Ophthalmology ed 4, Lippincott Williams and Wilkins, 2007.